

RANTES and fibroblast growth factor 2 in jawbone cavitations: triggers for systemic disease?

Johann Lechner¹
Volker von Baehr²

¹Clinic for Integrative Dentistry, Munich, Germany; ²Compartment of Immunology and Allergology on Institute for Medical Diagnostics in MVZ GbR, Berlin, Germany



Correspondence: Johann Lechner
Clinic for Integrative Dentistry,
Gruenwalder Str 10A,
81547 Munich, Germany
Tel +49 89 697 00 55
Fax +49 89 692 58 30
Email drlechner@aol.com

Background: Jawbone cavitations (JC) are hollow dead spaces in jawbones with dying or dead bone marrow. These areas are defined as fatty degenerative osteonecrosis of the jawbone or neuralgia-inducing cavitational osteonecrosis and may produce facial pain. These afflictions have been linked to the immune system and chronic illnesses. Surgical debridement of JC is reported to lead to an improvement in immunological complaints, such as rheumatic, allergic, and other inflammatory diseases (ID). Little is known about the underlying cause/effect relationship.

Objectives: JC bone samples were analyzed to assess the expression and quantification of immune modulators that can play a role in the pathogenesis of IDs. The study supports a potential mechanism where JC is a mediating link in IDs.

Materials and methods: Samples of fatty softened bone taken from JCs were extracted from 31 patients. The specimens were analyzed by bead-based multiplex technology and tested for seven immune messengers.

Results: Regulated upon activation, normal T-cell expressed, and secreted (RANTES) and fibroblast growth factor (FGF)-2 were found at high levels in the JCs tested. Other cytokines could not be detected at excessive levels.

Discussion: The study confirms that JC is able to produce inflammatory messengers, primarily RANTES, and, secondarily, FGF-2. Both are implicated in many serious illnesses. The excessive levels of RANTES/FGF-2 in JC patients with amyotrophic lateral sclerosis, multiple sclerosis, rheumatoid arthritis, and breast cancer are compared to levels published in medical journals. Levels detected in JCs are higher than in the serum and cerebrospinal fluid of amyotrophic lateral sclerosis and multiple sclerosis patients and four-fold higher than in breast cancer tissue.

Conclusion: This study suggests that JC might serve as a fundamental cause of IDs, through RANTES/FGF-2 production. Thus, JC and implicated immune messengers represent an integrative aspect of IDs and serve as a possible cause. Removing JCs may be a key to reversing IDs. There is a need to raise awareness about JC throughout medicine and dentistry.

Keywords: RANTES/CCL5, fibroblast growth factor, FGF-2, bead-based Luminex analysis, osteolytic degenerated jaw bone, NICO, systemic signaling pathways

Background and aim of the study

Jawbone cavitations (JCs) are hollow dead spaces in the jawbone where the bone marrow is dying or dead. These fatty degenerative dead areas or cavitations may produce facial pain but they can also be present for years as an asymptomatic process. The term neuralgia-inducing cavitational osteonecrosis (NICO) has been defined by Bouquot et al^{1,2} as a hollow space produced by osteolysis. However, the possible systemic effects of NICO on the organism are not described by this nomenclature. JCs have long been believed to interfere with the immune system and have been

suspected to be a factor in many chronic illnesses. However, the status of messengers of immune activation in samples of degenerated jawbone tissue/NICO has not been widely assessed to date.³ Hidden immune messengers in abnormal jawbones could support a mediating link between NICO lesions and systemic disease (SD). The aim of this study is to verify the hypothesis that certain immune mediators present in NICO are important in SD. The study is patient centered, with samples and data obtained directly from patients from the corresponding author's practice, but does not present case histories. The study supports an expanded immunological signaling network in the involvement of JCs.

Diagnostic problems of NICO lesions in the jawbone

The existence of NICO is largely neglected today in mainstream dentistry. The reason for this is that conventional X-ray techniques are limited in their ability to reveal the actual extent and location of JCs. To aid the practitioner in diagnosing the debilitating effects of bone marrow softening inside NICO lesions, a computer-assisted through-transmission alveolar ultrasound (TAU) device was developed.⁴ TAU precisely images and identifies cavitation porosity in the jawbone. Studies show that, in 84% of cases, NICO lesions in TAU images were more obvious and more readily identified than on radiographs of the same site. TAU imaging proved significantly superior to radiology for the detection of microscopically confirmed NICO. The efficiency and reliability of TAU in the diagnosis and imaging of NICO has been presented in numerous publications.^{4,5} Because of these diagnostic difficulties, jawbone disease is underdiagnosed by dentists.

Morphological definition of fatty degenerative osteolysis of the jawbone/NICO

Osteopathies of the bone and, in particular, of the jawbone are subject to different definitions and classifications. In the last few years, it has become increasingly apparent that intravascular coagulation plays a significant role in the pathogenesis of the osteonecrosis.^{6,7} Nevertheless, it is very difficult to define precise pathophysiology and cell biology of the osteonecrosis. The term osteonecrosis is used to describe a condition influenced by a wide range of factors and further research is required to fully understand the cell biology and to identify its cause.⁸ There is a clear difference between JC defined as NICO and the classical form of acute or chronic osteomyelitis. NICO is similar to silent

inflammation or subclinical inflammation with typical signs of subliminal inflammation and painlessness.

The macroscopic features of the NICO bone samples we collected were similar in all 31 samples and, due to the softening of the spongy bone, the marrow space could be easily vacuumed and curetted. Degeneration of the cancellous bone extended in the mandibular areas as far as the canal of the inferior alveolar nerve. Bouquot et al describe NICO-induced necrotic, softened, cancellous bone as follows: hollow cavitations with soft tissue that have undergone fatty dystrophic changes and delamination of the bony sheath of the inferior alveolar nerve.^{1,4} The extent of these lesions was documented in an earlier publication.⁹ Figures 1 and 2 show a sample with predominant fatty transformation of the jawbone.

Pathohistological definition of fatty degenerative osteolysis of the jawbone/NICO

Each of the NICO samples in the present study were examined histopathologically, and it was found that the trabeculae were thin with a loss of their bony interconnections. The fatty marrow showed mucoid degeneration with interstitial edema. These chronic degenerative changes were intermingled with foci of recent areactive adipocyte necrosis with granular dissolution of the cytoplasm. The amount of fat cells was consistently and strikingly increased. Typical signs of inflammation, especially of an inflammatory cell response, were absent. The fatty degenerative and osteolytic aspects occurred due to insufficient metabolic supply. Widened intertrabecular spaces often contained small necrotic bone fragments. Fatty microvesicles and pools of liquefied fat similar to oil cysts, with almost complete loss of adipocyte nuclei and residual fatty degenerated marrow, were also present. Marrow showed an accumulation of acid mucopolysaccharides that stained positive with Alcian blue (see figure 3). Small nerve fibers are a striking feature of most JC biopsies, and are situated in close contact with degenerated and necrotic fatty tissue.¹⁰

Materials and methods Cohort of patients

We collected JC tissue samples from 31 patients. Inclusion criteria of the studied population were patients with systemic immunological or neurodegenerative diseases and local diagnosis of NICO in the jawbone. Patients taking any medications due to systemic complaints were not excluded from the study. We analyzed regulated upon activation,

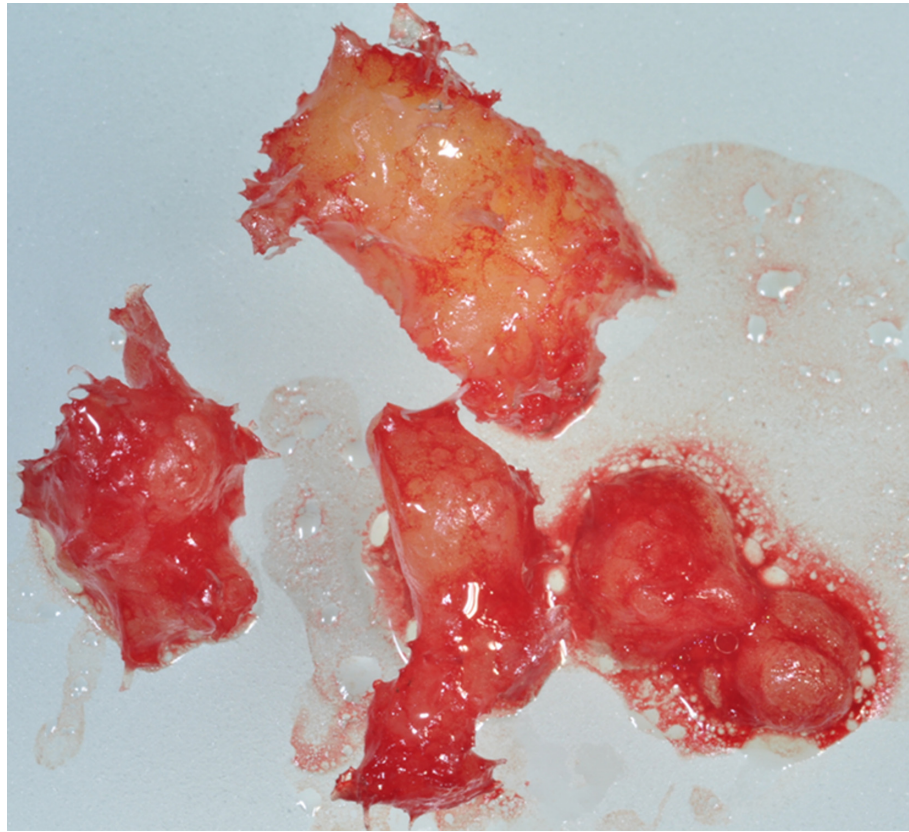


Figure 1 NICO sample completely converted to fatty spongy marrow of the jawbone.
Abbreviation: NICO, neuralgia-inducing cavitational osteonecrosis.

normal T-cell expressed, and secreted (RANTES)/C-C motif chemokine 5 (CCL5) (hereafter referred to as RANTES) and fibroblast growth factor (FGF)-2 expression in NICO in these 31 patients, and in serum ($n = 14$). The following symptoms were present in the 31 patients (multiple counts are due to overlapping symptoms): seven patients with nonspecific facial pain/trigeminal neuralgia; seven patients with joint aches or rheumatoid arthritis (RA); four patients with chronic fatigue syndrome; five patients with breast cancer (BC); three patients with autoimmune disease of the thyroid gland (Hashimoto's thyroiditis); two patients with multiple sclerosis (MS); one patient with Parkinson's disease; one patient with asthma; one patient with leukemia (cured); one patient with allergy/intolerance; and one patient with amyotrophic lateral sclerosis (ALS).

Inclusion criteria for the JC group were the medical indication for NICO surgery in these patients based on orthopantomogram X-rays (two-dimensional) and an additional cone beam X-ray (three-dimensional), and multiple and irregular remnants of lamina dura present in a subtle radiolucent background, leading to the suspicion of the presence of JC. The definite indication for NICO

surgery is from the complementary evaluation of additional measurement of bone density by TAU. Demographic data of the 31 cases in the NICO cohort were average age (57.1 years, range 36–86 years) and sex (female:male 21:10).

Additionally, we collected tissue samples from the normal jawbones of three patients who gave their consent for bone specimen collection during implantation and analysis. Inclusion criteria for this cohort were no radiographic evidence of NICO and inconspicuous measurement of bone density by TAU. Patients showed no systemic health risks.

Sampling of NICO tissue

In the corresponding author's Clinic for Integrative Dentistry, 31 patients diagnosed with NICO had surgery on the affected area of the jaw after local anesthesia and folding of a mucoperiosteal flap. The cortical layer was removed. All 31 patients showed osteolytic spongy areas and degenerative fatty tissue, as described in the "Background" section of this paper. In all cases, surgery was performed on edentulous jaw areas in the range of former wisdom teeth and the adjacent retromolar areas; there were 15 JC cases in the upper jaw and 16 in the lower jaw.

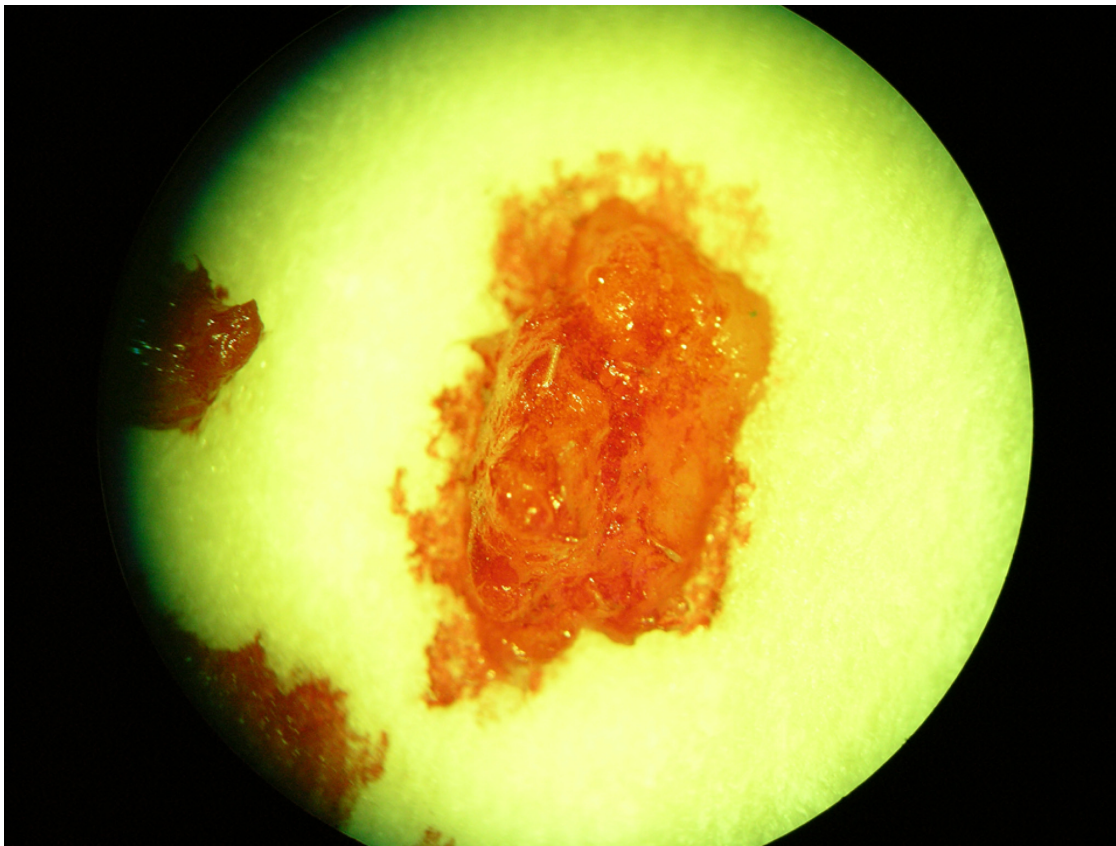


Figure 2 Microscopic view of NICO sample completely converted to fatty spongy marrow of the jawbone.

Abbreviation: NICO, neuralgia-inducing cavitational osteonecrosis.

Measurement of RANTES/FGF-2 in NICO samples and serum

The necrotic tissue samples ($n = 31$; see Figures 1 and 2) with a volume up to 0.5 cm^3 were stored in a dry, sterile, 2 mL collecting vial (Sarstedt AG and Co, Nümbrecht Germany), which was made air tight, and frozen at -20°C . In 14 of these patients, serum was taken intravenously directly before or concomitantly after NICO surgery with a heparinized 7.5 mL collection tube (Sarstedt) and immediately frozen.

Processing of necrotic tissue samples

In the laboratory, the samples were homogenized by mechanical force in 200 μL of cold protease inhibitor buffer (Complete Mini Protease Inhibitor Cocktail; Roche Diagnostics GmbH, Penzberg, Germany). The homogenate was centrifuged for 15 minutes at 13,400 rpm. Afterwards, the supernatant was collected and centrifuged for another 25 minutes at 13,400 rpm.

Measurement of RANTES/FGF-2

In the 31 supernatants of tissue homogenate, we measured RANTES, FGF-2, interleukin (IL)-1 receptor antagonist

(ra), IL-6, IL-8, monocyte chemoattractant protein-1 (MCP1), and tumor necrosis factor-alpha (TNF- α). In 14 patients in the NICO cohort, RANTES and FGF-2 were also analyzed in serum. Measurement was performed using the Human Cytokine/Chemokine Panel I (MPXHCYTO-60K; Merck KGaA, Darmstadt, Germany) according to the manufacturer's instructions and analyzed using the Luminex[®] 200[™] with xPonent[®] Software (Luminex Co, Austin, TX, USA). For measurement of RANTES in serum, samples were prediluted 1:100 in sample buffer according to manufacturer's instructions (see Figure 4).

Results

The results of the analysis of the seven cytokines in the NICO cohort ($n = 31$) are shown in Figure 3 (note the high amounts of IL1-ra, RANTES, and FGF-2). IL1-ra showed a median of 834.10 with a standard deviation of 1742.241 and percentile 25 of 60.80. RANTES showed a median of 3810.9 with a standard deviation of 2566.9 and percentile 25 of 2085.4. FGF-2 showed a median of 499.8 with a standard deviation of 383.5 and percentile 25 of 177.9. There was a correlation between FGF-2 and RANTES in NICO tissue

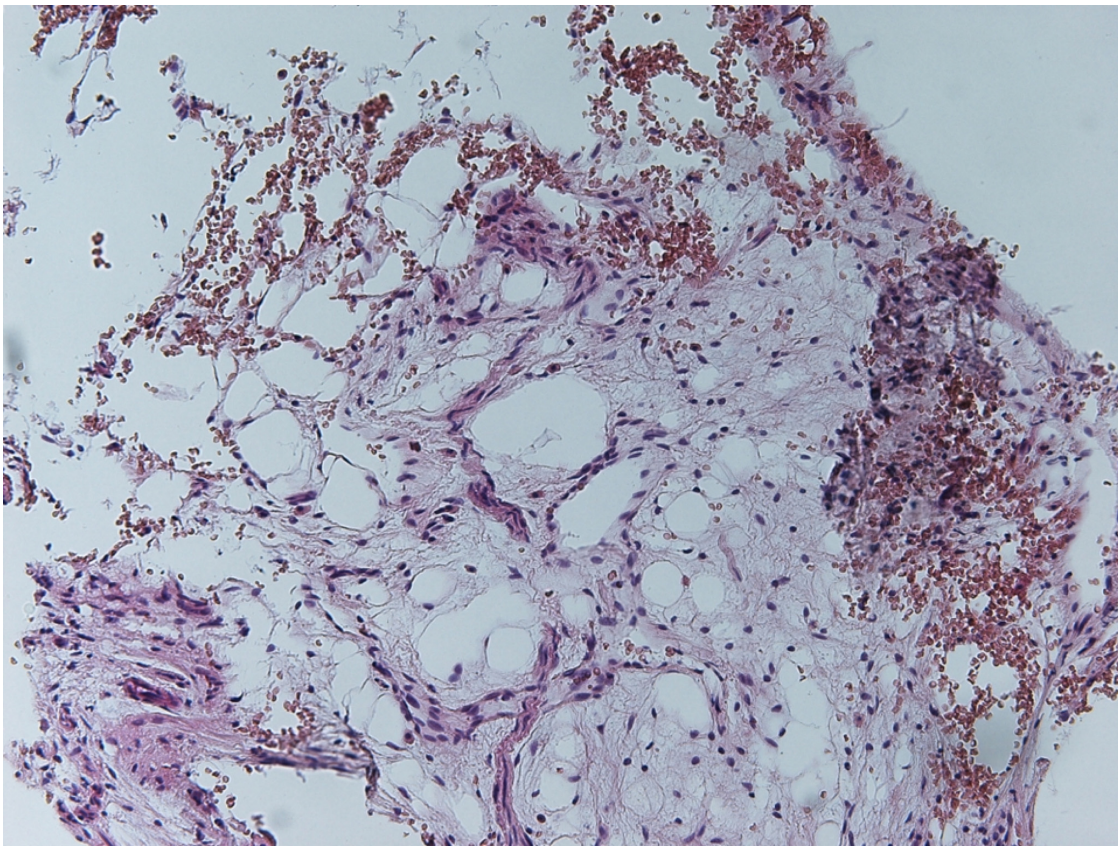


Figure 3 Pathohistological structure of typical NICO tissue.
Abbreviation: NICO, neuralgia-inducing cavitational osteonecrosis.

($P < 0.01$; Spearman-Rho correlation coefficient 0.607), but not between other mediators.

The results of the three samples of normal jawbone were as follows (pg/mL): IL1-ra, 227.4, 92.5, and 863.7; RANTES, 217.8, 322.6, and 3.5; FGF-2, 14.4, 35.5, and 5.6, respectively. Values for healthy patients and normal jawbones were not available for comparison in the literature. Figure 3 shows the mean values comparing the expression of the seven cytokines in these controls with NICO patients.

Concentration and distribution of RANTES in NICO tissue and serum

RANTES in NICO tissue assigned to clinical disease

Although the mean value of RANTES in NICO tissue was strongly elevated, the individual values of the 31 NICO samples are also of note as they allow the interpretation of the pathogenic significance of RANTES with reference to their concomitant clinical conditions. Figure 6 shows the RANTES levels of the 31 NICO patients according to their clinical diseases and problems. Comparison of matched serum and NICO samples from individual patients indicated a nonsignificant trend towards higher levels of RANTES in NICO. Correlation coefficients

of RANTES tissue levels to serum levels was -0.130 , and not significant (data not shown).

Concentration and distribution of FGF-2 in NICO tissue and serum

FGF-2 in NICO tissue assigned to clinical disease

The results of FGF-2 in the 31 NICO tissue samples reveal an average value of 536.01 pg/mL. Figure 7 shows FGF-2 tissue levels of the NICO cohort according to their clinical diseases and problems. FGF-2 levels were also assessed in a subset of serum samples ($n = 14$). Comparison of matched serum and NICO samples from individual patients indicated a nonsignificant trend towards higher levels of FGF-2 in NICO patients relative to controls. Serum levels of FGF-2 in the 14 NICO patients were an average of 84.29 pg/mL, with a median of 27.72 and a standard deviation of 157.65, and percentile 25 of 15.70; there was no significant correlation between FGF-2 in NICO and serum (data not shown).

Discussion

We are aware that three samples of normal jawbone is a small sample size. This limitation notwithstanding, the aim of this

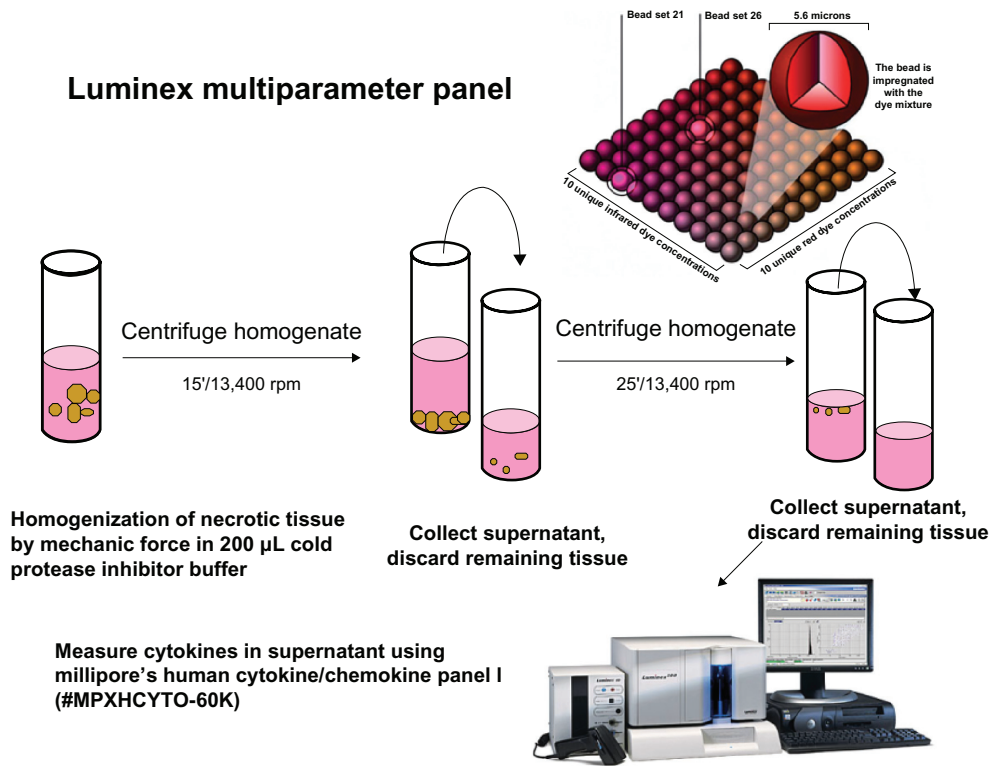


Figure 4 Bead-based processing of NICO samples.

study was to obtain an initial insight as to whether cytokine levels in NICO are conspicuous.

NICO is a chronic, insidious, and subtle process. This is supported by the fact that typical acute proinflammatory cytokines, such as TNF- α and IL-6, were not increased.

The absence of acute inflammation denotes that the proliferation of chronic immunological processes is under the guidance of RANTES/FGF-2. In contrast to RANTES and FGF-2, IL-1-ra acts as a strong anti-inflammatory mediator by blocking signal transduction at the IL1 receptor level.¹¹

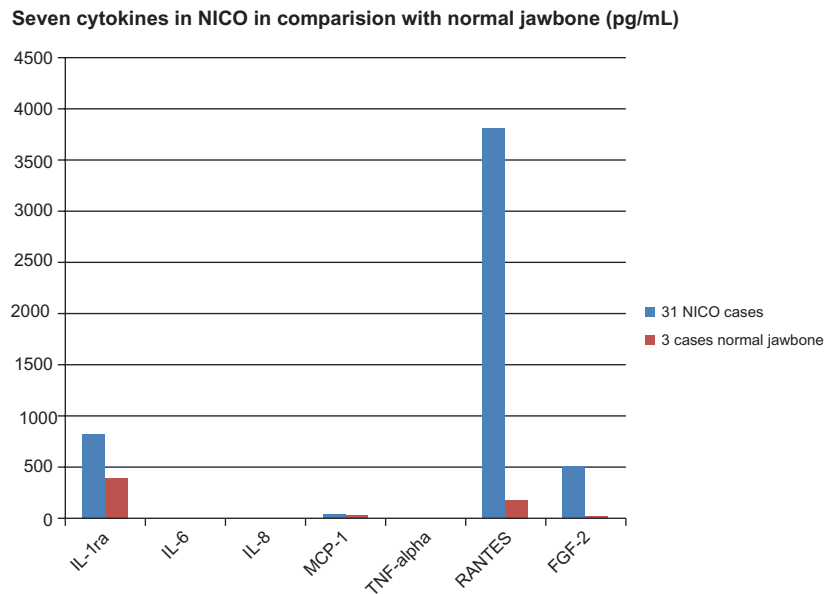


Figure 5 Distribution of seven cytokines in NICO (n = 31) and in normal jawbone (n = 3) (values in pg/mL).

Abbreviations: FGF-2, fibroblast growth factor 2; IL, interleukin; MCP-1, monocyte chemoattractant protein 1; NICO, neuralgia-inducing cavitation osteonecrosis; ra, receptor antagonist; RANTES, regulated upon activation normal T-cell expressed and secreted/chemokine ligand 5; TNF, tumor necrosis factor.

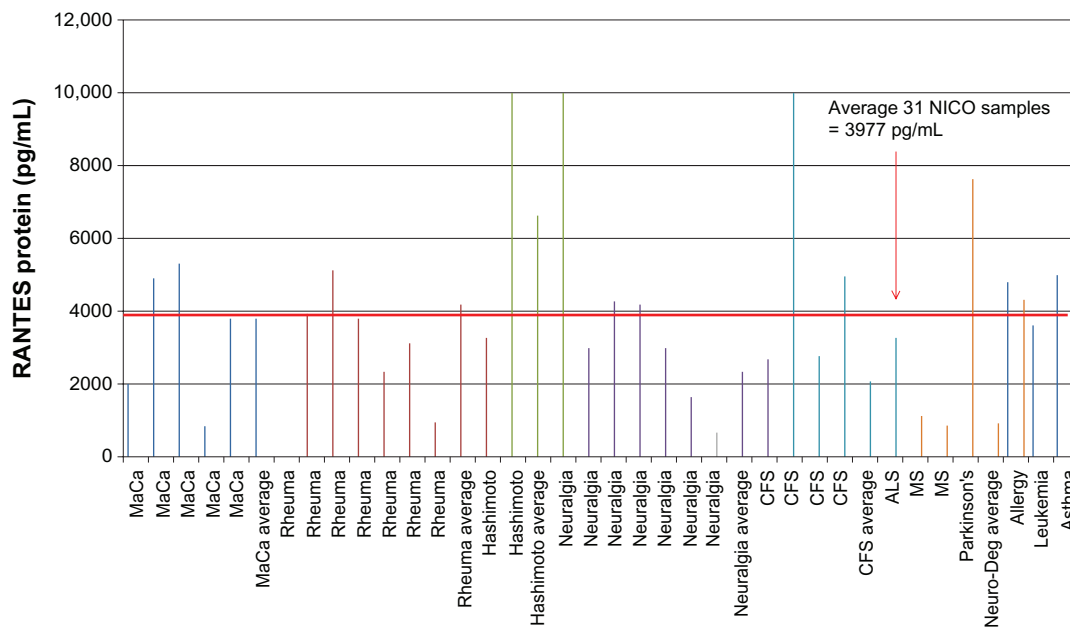


Figure 6 RANTES in NICO tissue with cohort assigned to diseases.

Abbreviations: ALS, amyotrophic lateral sclerosis; CFS, chronic fatigue syndrome; MaCa, breast cancer; MS, multiple sclerosis; Neuro-Deg, neurodegenerative disease; NICO, neuralgia-inducing cavitational osteonecrosis; RANTES, regulated upon activation, normal T-cell expressed, and secreted/chemokine ligand 5; Rheuma, rheumatoid arthritis.

Due to the anti-inflammatory effects of IL1-ra, we did not find common signs of inflammation in NICO. The most striking discovery of the present study is that high levels of RANTES and FGF-2 were found in 30 of the 31 NICO tissues investigated (see Figure 6). Correlations between levels of RANTES and FGF-2 in NICO tissue were statistically significant. The high levels of RANTES/FGF-2 in NICO patients indicate that NICO can be described as a detailed

metabolic pattern, causing similar and mutually reinforcing pathogenic signaling pathways in other organs. The immune system seems to be activated in response to danger signals, which evoke various innate molecular pathways that culminate in inflammatory cytokine production and possible activation of the adaptive immune system. This integrative aspect requires us to take a closer look at RANTES and FGF-2 and their role in diseases.

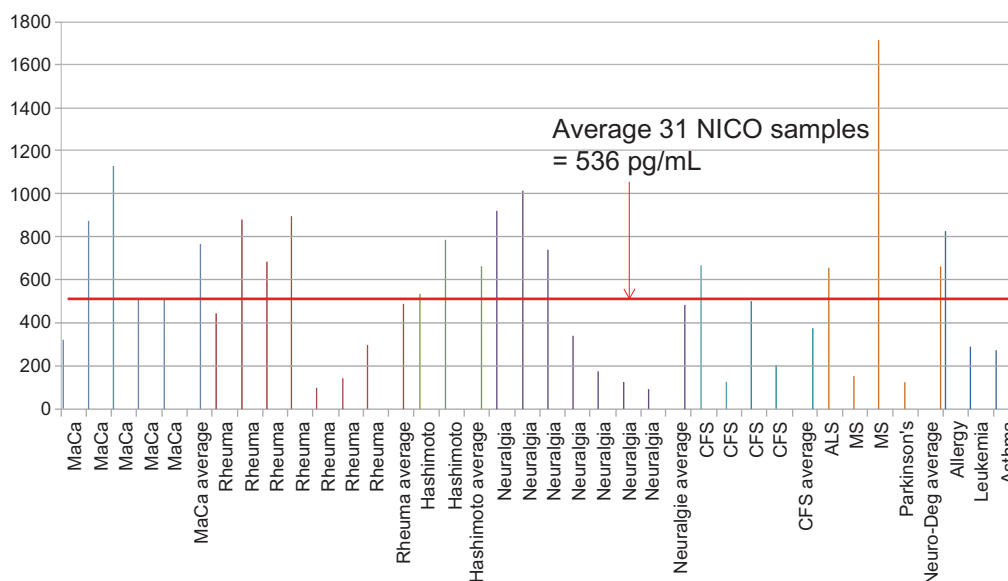


Figure 7 Assignment of FGF-2 levels (pg/mL) in 31 NICO samples to diseases.

Abbreviations: ALS, amyotrophic lateral sclerosis; CFS, chronic fatigue syndrome; FGF-2, fibroblast growth factor 2; MaCa, breast cancer; MS, multiple sclerosis; Neuro-Deg, neurodegenerative disease; NICO, neuralgia-inducing cavitational osteonecrosis; RANTES, regulated upon activation, normal T-cell expressed, and secreted/chemokine ligand 5; Rheuma, rheumatoid arthritis.

Characteristics of RANTES

RANTES belongs to the family of chemotactic cytokines known as chemokines. RANTES is produced by circulating T-cells and plays an active role in recruiting leukocytes to inflammatory sites. Studies have demonstrated that RANTES is implicated in many serious illnesses: the chemotactic activities of RANTES route T-cells, dendritic cells, eosinophils, NK cells, mast cells, and basophils to sites of inflammation and infection.¹² However, RANTES can have detrimental effects via the recruitment of immune cells that enhance inflammatory processes, such as in arthritis, atopic dermatitis, nephritis, colitis, and other disorders.¹³ RANTES targets the central nervous system and promotes MS and Parkinson's disease. When targeting mast cells, RANTES is involved in allergies, alopecia, and thyroid disorders.¹⁴ Proinflammatory chemokines such as RANTES also act on neurons, and RANTES is also involved in diseases of the central nervous system.¹⁵ The influence of RANTES on astrocytes is a further association of RANTES and the central nervous system.¹⁶ RANTES is also excreted by human melanoma cells and has been shown to accelerate tumor growth in a murine disease model.¹⁷ In Hodgkin's disease, malignant Reed–Sternberg cells produce RANTES, which provokes chemotactic migration of mast cells into the tumor tissue. Hodgkin's lymphoma cell lines also express RANTES *in vivo*.¹⁸

Fatty tissue and adipocytes in NICO create RANTES

Why were strikingly high RANTES levels found in our analysis of NICO? Fatty tissue in general is seen today as an active part of the endocrine and immune systems. Our data render a discussion about the RANTES secretion by NICO fatty tissue necessary, as reduced blood flow and capillary density followed by ischemia can lead to a hypoxic situation.¹⁹ The diameter of adipocytes in obesity exceeds the range of diffusion of O₂ inside tissues (approximately 120 nm), and this alone can induce local hypoxia. Adipocytes are triggers of silent inflammation: it is well known that fat cells release inflammatory cytokines.²⁰ In our histological NICO findings, necrobiotic modified adipocytes were regularly found. Interestingly, a remarkable difference in the cytokine patterns of body fat and NICO exists. For instance, while in obesity increased levels of TNF- α and IL-6 play important roles with regard to systemic effects, these mediators did not show up in NICO samples. The existence of high levels of RANTES in NICO is confirmed by a recent study on macrophages and RANTES in fatty tissue, as macrophages are not the only inflammatory cells that are found in the adipose tissue of obese patients. Recently, T-lymphocytes

were also detected in the adipose tissue in obese patients and in mouse models of obesity.²¹ T-lymphocytes are also attracted by chemokines.²² Huber et al found increased expression of RANTES in fatty tissue in obese patients.²³ Therefore, the immune effects elicited by fatty tissue and our understanding of NICO adipose tissue (see Figures 1 and 2) is an issue and will be further illuminated in this discussion.

Comparison of RANTES expression in NICO to RANTES expression in pathological body tissues

As the role of RANTES as a key mediator in SD is well known in medical science, the following interesting question arises: how high are tissue levels of RANTES in malignancies and what data are available in literature? Niwa measured the RANTES content in primary malignancies.²⁴ Increased RANTES levels were found in all breast and cervical tumors examined. In 12 BC tissue samples, RANTES expression was 1.032 ± 120 pg/mLg and in cervical collar tumors it was 984 ± 115 pg/mLg.²⁴ Comparable high levels of RANTES expression have been found to be produced by BC cells (797.6 ± 3.96 pg/mL).²⁵ In RA, synovial fluid in infected joints of 15 patients revealed RANTES levels of 414 pg/mL, compared to the average of a healthy control cohort of ten patients, which was 59 pg/mL.²⁶ In tissue samples of cultured endometrial tissue 24 hours after stimulation with TNF- α at a concentration of 100 ng/mL, RANTES levels increased to 1950 pg/mL ($P < 0.0001$).²⁷ Figure 8 compares the mean RANTES levels in our cohort of NICO patients ($n = 31$; 3009.5 pg/mL) with RANTES levels of patients with BC, cervical carcinomas, RA, and endometriosis. It is obvious that NICO areas contain three-fold higher levels of destructive RANTES signaling compared to degenerative or chronic inflammatory tissue samples found in corresponding papers.^{24–27} If RANTES plays an important role in malignancies, then RANTES levels in NICO should also be included in pathogenic considerations and therapeutic objectives.

Characteristics of FGF-2

Growth factors are key regulators of proliferative and migratory events and FGFs play a role in wound repair,²⁸ which is characterized by both cellular proliferation and migration. FGFs and their receptors drive crucial developmental signaling pathways, which are responsible for many functions, including cell proliferation, survival, and migration.²⁹ As such, they are susceptible to being hijacked by cancer cells and have been shown to have oncogenic roles in many cancers.^{30,31} Understanding

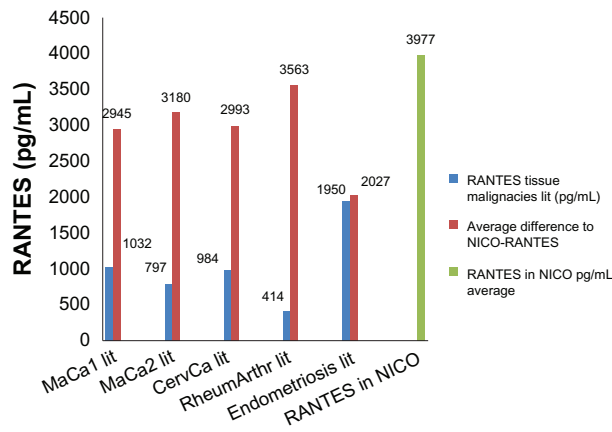


Figure 8 RANTES levels in pathological tissues and mean difference compared to RANTES expression in the NICO cohort.

Abbreviations: CervCa, cervical cancer; lit, data from literature; MaCa, breast cancer; NICO, neuralgia-inducing cavitation osteonecrosis; RANTES, regulated upon activation, normal T-cell expressed, and secreted/chemokine ligand 5; RheumArthr, rheumatoid arthritis.

more about context-specific FGF signaling is a key area of study.³² As FGF-2 is also produced by adipocytes and affects bone metabolism, the characteristic fatty portions of NICO with high contents of adipocytes is a presumable source of FGF-2.

FGF-2 and its role in malignancies

The above background information on FGF-2 and data from NICO samples suggest focusing on FGF-2 in a short overview. Participation of FGF-2 is implicated in many diseases.³³ For instance, findings suggest that prostatic FGF-2 activity may promote tumor progression and support the hypothesis that FGF-2 plays a significant role in prostate cancer progression in vivo.³⁴ FGF-2 is highly expressed in late-stage prostate cancer and may promote angiogenesis, allowing tumors to grow and metastasize.^{35,36} The ability to produce FGF-2 may stimulate angiogenesis, allowing the cells to metastasize.^{37,38} Patients with colorectal cancer have elevated FGF-2 levels in their serum and plasma compared to cancer-free controls.³⁹ The highest levels of serum FGF-2 were detected in patients with tumor metastasis and this was associated with reduced patient survival.³⁹ These findings demonstrate that FGF-2 expression levels in colorectal³⁹ cancer are correlated with cancer progression, metastasis, prognosis, and patient survival.⁴⁰ Le Page et al report that FGF-2 levels are elevated in the serum of patients with ovarian cancer compared to cancer-free individuals and in tumor tissue compared to non-tumorous tissue.⁴¹ Also, patients with gastric carcinoma have significantly higher levels of FGF-2 in their serum compared to cancer-free patients.⁴²

Comparison of FGF-2 expression in NICO with FGF-2 expression in pathological body tissue

As FGF-2 expression is enhanced in NICO, we decided to profile FGF-2 across other pathological tissues. Our comparative data findings from the literature are as follows:

- Giri et al⁴³ directly analyzed biopsies from prostate cancers and uninvolved prostatic peripheral zone tissue by enzyme-linked immunosorbent assay. For FGF-2, a total of 31 cancer and eleven normal peripheral zone extracts were analyzed and two-thirds of the cancers had higher FGF-2 concentrations than the highest uninvolved tissue; some cases had extremely high levels of FGF-2 (>400 ng/g tissue). The mean concentration of FGF-2 in the prostate cancer samples was markedly increased relative to control tissue, with a mean FGF-2 concentration of 271 ng/g wet weight of tissue versus 110 ng/g wet weight for uninvolved peripheral zone.
- Dabrosin⁴⁵ measured extracellular levels of FGF-2 in normal breast tissue in vivo at 14.0 pg/mL using microdialysis in eleven premenopausal and five postmenopausal women. There was no significant difference between the levels in premenopausal woman and postmenopausal women ($P = 0.66$). This data is included in Figure 9.
- Relf et al⁴⁴ detected FGF-2 protein in every BC tumor. FGF-2 was also assessed by enzyme linked immunosorbent assay and expression was higher in tumors relative to normal breast tissues in cancer patients (median, 346 pg/mL

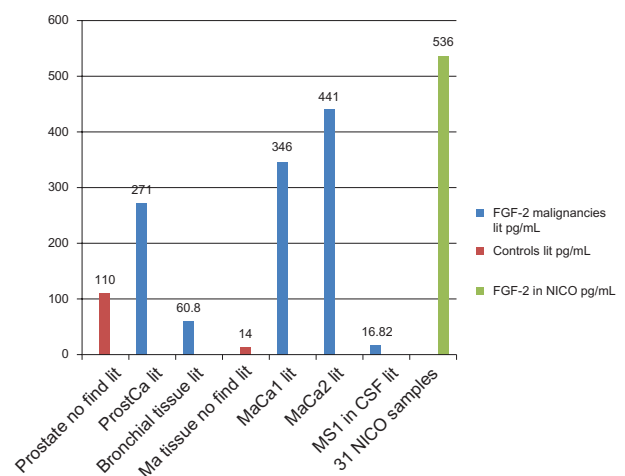


Figure 9 FGF-2 levels in pathological tissues and mean difference compared to FGF-2 expression in the NICO cohort.

Abbreviations: FGF-2, fibroblast growth factor 2; lit, data from literature; MaCa, breast cancer; Ma tissue no find, breast tissue no pathological findings; MS, multiple sclerosis; NICO, neuralgia-inducing cavitation osteonecrosis; ProstCa, prostate cancer.

cytosol; range, 54–1323 pg/mL; versus controls: median, 149 pg/mL; range, 32–509 pg/mL; $P = 0.01$).

- Smith et al⁴⁶ detected basic FGF in all 149 tumor cytosols and 21 nontumor cytosols analyzed in their study. In the tumor cytosols the FGF-2 levels ranged between 27–12,662 pg/mg, with a median of 441 pg/mg of protein. In the nontumor cytosols ($n = 14$) taken from a site away from the tumor, the FGF-2 levels ranged from 32–509 pg/mg, with a median of 149 pg/mg of protein. These results show that malignant breast lesions contain significantly higher levels of FGF-2 compared to normal tissue, implying an involvement of FGF-2 in breast carcinogenesis.

The distribution of mean levels of the FGF-2 tissue of the cohorts and controls quoted from the above literature from two studies of BC, cancer, prostate carcinoma, and MS and from two nonaffected healthy controls of breast and prostate are all below the averages of the NICO cohort ($n = 31$) that had an expression average of 536 pg/mL. Also, sampled NICO areas contain more FGF-2 signaling compared to cerebrospinal fluid (CSF) samples from MS patients or in carcinoma tissue in BC or prostate cancer.

Role of RANTES and FGF-2 from NICO in three specific malignancies

Data presented in this study support the hypothesis of inflammation inducing NICO sites in jawbones, promoting the pathogenesis of different IDs/SDs by immune mediator expression. The present findings implicate NICO-derived RANTES/FGF-2 as a building block for ID/SD. The initial question regarding the role of RANTES and FGF-2 in NICO areas can be elucidated when evaluated in the context of patients with BC or those with RA or neurodegenerative diseases.

RANTES and FGF-2 and their roles in breast cancer

RANTES has also been associated with the induction or promotion of cancer.⁴⁷ Development of BC is reliant on the potential ability of RANTES to act directly on the tumor cells and to promote tumor progression.⁴⁸ RANTES levels were markedly elevated in the primary tumor and metastatic lesions from all patients with BC or cervical cancer. This study suggests an as yet undefined but important role for RANTES in carcinogenesis.⁴⁹ RANTES was significantly increased in BC cases with no metastasis and it was also highly significantly increased in metastatic patients compared to controls.⁵⁰ RANTES may also be involved in the formation of BC metastasis: stem cells transform individual tumor cells

into metastasizing cells using transmitters like RANTES.⁵¹ This increased propensity towards metastasis is reversible and dependent on RANTES signaling.⁵² Karnoub et al⁵³ suggest that those stem cells with the aid of messengers transmute tumor cells into metastasizing cells and therefore conclude that RANTES stimulates metastasis. BC cells stimulate de novo secretion of RANTES from mesenchymal stem cells, which then acts in a paracrine fashion on cancer cells to enhance their motility, invasion, and metastasis.⁵³

FGF-2 is an angiogenic and mitogenic factor in BC. Smith et al reported FGF-2 levels more than ten-fold higher in tumor cytosols compared to adjacent normal breast tissue.⁴⁵ In vitro experiments have shown that BC cells contain FGF-2 and FGF-2 can accelerate or restrain the growth of BC cells.⁵³ These results provide evidence for a possible role of FGF-2 in the activation of neovascularization in inflammatory BC. Figure 10 compares RANTES and FGF-2 levels derived from NICO samples in five BC patients to levels found in literature for corresponding BC cohorts: RANTES expression inside NICO in each of the five BC patients is much higher than levels found in BC tissue itself. Likewise, FGF-2 levels derived from NICO in each of the five BC patients are comparable to levels reported in the literature.^{46,54} The presented NICO analysis lends support to the possible involvement of specific immunoreactive patterns of RANTES/FGF-2 expression in JC using the above-cited pivotal effects of RANTES/FGF-2 in BC as evidence.

RANTES and FGF-2 and their role in rheumatoid arthritis

RANTES is secreted by the inner synovia into synovial fluid and is involved in a progressive inflammatory process in RA. By expressing RANTES, synovial fibroblasts may participate in the ongoing inflammatory process in RA.^{55,56} RA is characterized by recruitment of leukocytes from the vasculature into inflamed synovial tissue and synovial fluid, which depends, in part, upon the continued maintenance of chemotactic stimuli like RANTES.⁵⁷ The selective chemoattractant and activation effects of chemokines on leukocytes identify them as potentially ideal candidates for mediating selective inflammatory processes in RA.⁵⁸ There is increasing evidence suggesting a role for RANTES in the pathogenesis of RA.⁵⁹ For instance, RANTES was found to be a key molecule in the pathogenesis of all onset cohorts of juvenile RA.⁶⁰ Figure 11 compares RANTES/FGF-2 expression in NICO areas in four RA patients with levels of corresponding controls. It is evident that RANTES levels in each of the four NICO RA cases exceeded RANTES

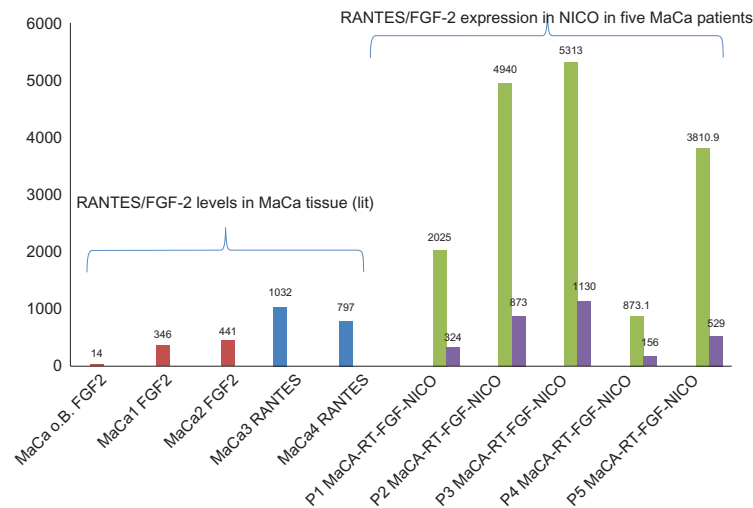


Figure 10 Comparison of RANTES and FGF-2 expression (pg/mL) in BC tissues and in NICO in five BC patients.

Abbreviations: BC, breast cancer; FGF-2, fibroblast growth factor 2; lit, literature; MaCa o.B., MaCa, breast cancer; NICO, neuralgia-inducing cavitation osteonecrosis; RANTES, regulated upon activation, normal T-cell expressed, and secreted/chemokine ligand 5.

expression found directly in the synovial fluid of RA patients. FGF-2 expression in each of the four NICO RA cases is much higher when compared to levels from normal uninvolved peripheral-zone extracts taken from prostate cancer and BC tissue.

RANTES and FGF-2 and their role in neurodegenerative diseases

The authors' initial hypothesis – that certain immune mediators derived from NICO can play a role in relevant immunoreactivity – is corroborated by other research.

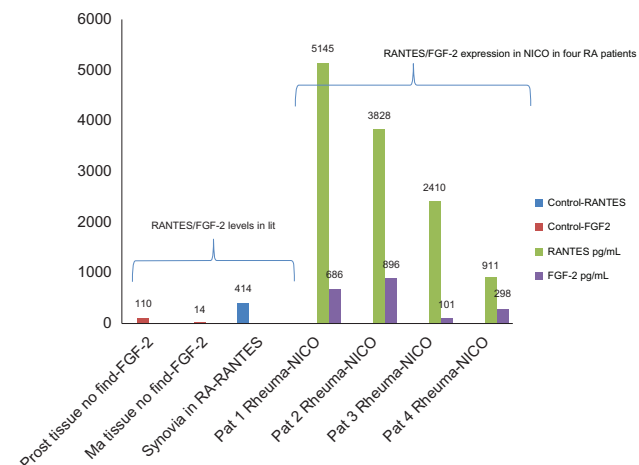


Figure 11 Comparison of RANTES/FGF-2 (pg/mL) in synovial fluid in RA and NICO in four RA patients.

Abbreviations: FGF-2, fibroblast growth factor 2; lit, data from literature; NICO, neuralgia-inducing cavitation osteonecrosis; RANTES, regulated upon activation, normal T-cell expressed, and secreted/chemokine ligand 5; RA/ Rheuma, rheumatoid arthritis; Prost tissue, prostate tissue with no pathological findings; Ma tissue, breast tissue with no pathological findings.

Sarchielli et al⁶¹ found elevated FGF-2 levels in the CSF of MS patients. In recent years, a role has been recognized for FGF-2 in the pathogenesis of demyelination and the failure of remyelination in experimental models of MS. Findings support the implication of FGF-2 in the pathogenesis of MS. FGF-2 levels in the CSF of MS patients were significantly higher than controls ($P < 0.001$ and $P < 0.05$, respectively).^{61–63} The highest levels were detected in MS patients during relapse.⁶¹ Other study cohorts found serum FGF-2 levels (mean 5.8 pg/mL) significantly increased within conventional MS patients (MS2 serum/MS2 controls in Figure 12) compared to a control cohort of 20 patients (mean 3.7 pg/mL; $P = 0.0291$).⁶² Johansson et al realized from increased levels in serum and in CSF from patients with ALS patients that FGF-2 is involved in the pathophysiological chain of this disease. FGF-2 was detected in CSF in eleven of 15 ALS patients (range 0.52–5.8 ng/mL) but in none of the ten controls ($P < 0.001$).⁶³ Comparison of these levels with the FGF-2 levels from NICO of two MS patients and one ALS patient is a significant contribution to a mediator-based approach of systemic interference.

Summary of discussion

NICO: a local site of chronic inflammation in the jawbone

JCs and NICO areas tend to disperse and not heal without surgical curettage. The hitherto misjudged actual existence of NICO seems to be proven by the following aspects: (1) NICO is characterized morphologically and macroscopically by fatty degenerative softening and osteolysis of the jawbone; (2) NICO is characterized

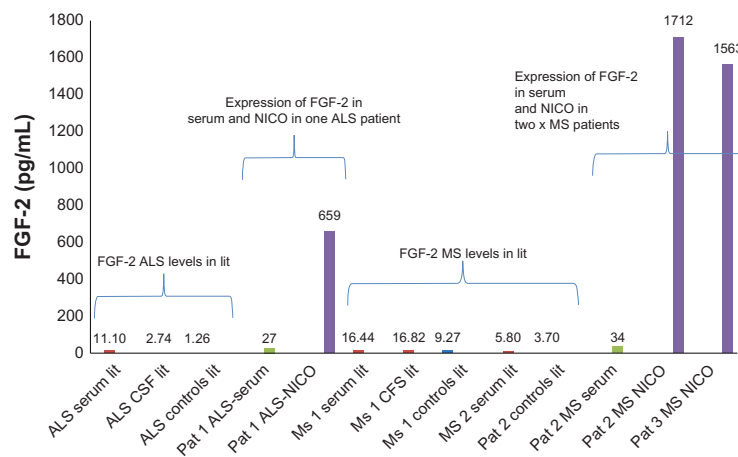


Figure 12 Comparison of FGF-2 levels in serum/CSF/control from literature with FGF-2 levels in NICO in one patient with ALS and two patients with MS.

Abbreviations: ALS, amyotrophic lateral sclerosis; CSF, cerebrospinal fluid; FGF-2, fibroblast growth factor-2; lit, data from literature; MS, multiple sclerosis; NICO, neuralgia-inducing cavitation osteonecrosis; Pat, patient with.

on histopathological and microscopic examination by resolution and propagation of adipocytes, a jelly-like substance inside the resolution, metabolic disturbance, and total lack of typical leukocytic inflammation; (3) NICO is characterized biochemically by significantly higher levels of the proinflammatory chemokine RANTES and growth factor FGF-2 in 30 of 31 samples compared to normal jawbones; (4) NICO is characterized biochemically by the absence of acute cytokines such as TNF- α and IL-6. This explains the painless and cryptic nature of NICO, which make its clinical acceptance in the daily practice difficult. Items 1 to 4 in the list above indicate that NICO areas are not normal; rather, they are pathological states of the jawbone.

NICO: a systemic pathogenically relevant phenomenon

Presented data and submitted contexts suggest that existing NICO areas in the jawbone can act as a significant pathogenic potential to the overall system: (1) adipocytes and the necrotic parts of fat cells are considered by many studies as immunologically active substances; (2) the average RANTES levels in 31 NICO samples is about three-fold as high as RANTES in BC tissue, in tissue cultures of cervix carcinomas and endometriosis, and extractions of rheumatic synovial liquid; (3) the average FGF-2 levels in 31 NICO samples are about two-fold as high as FGF-2 in prostate cancer tissue, in tissue of bronchial asthma, BC tissue, and in CSF from MS patients.

Limitations of the current study

Significance of the study lies in the relatively high number of NICO samples ($n = 31$) and the significant overexpression

of RANTES/FGF-2 in NICO sites. RANTES and FGF-2 levels inside NICO are significantly higher than tissue levels in certain malignancies. Limitations of the study lie in the multicausality and on the different syndromes that do not allow any evaluation of the clinical efficacy of NICO surgery.

Conclusion

Chronic inflammatory strain appears to be an important issue for integrative medicine. Although it is unknown to what extent increased expression of RANTES/FGF-2 in JC contributes to immune-mediated diseases, the above results provide evidence for the possible interaction between RANTES/FGF-2 signaling derived from NICO sites interacting with other organs. The hypothesis presented herein is based on the pathogenic aspects of NICO; corresponding individual setup provided, a permanent increase in RANTES/FGF-2 expression in NICO sites could exert negative impact in terms of joint inflammation or inflammatory signaling in the central nervous system and breast tissue. A comprehensive understanding of the complex networks outlined in this paper will require further research into the fundamental properties of cytokines and interleukins. The results submitted by the authors are therefore of a preliminary nature, but nevertheless provide a rationale for deregulated RANTES/FGF-2 expression within NICO having a causal role in a variety of ID/SD. The challenge posed by these discoveries is the need to raise awareness of JC through the medical and dental community. In order to clarify reliable causative backgrounds, this research can only highlight the need for a large multi-center prospective study with clearly defined cohorts.

Disclosure

The authors report no conflicts of interest in this work.

References

- Bouquot JE, Roberts AM, Person P, Christian J. Neuralgia-inducing cavitation osteonecrosis (NICO). Osteomyelitis in 224 jawbone samples from patients with facial neuralgia. *Oral Surg Oral Med Oral Pathol.* 1992;73(3):307–319.
- Bouquot JE, Christian J. Long-term effects of jawbone curettage on the pain of facial neuralgia; treatment results in neuralgia-inducing cavitation osteonecrosis. *Oral Surg Oral Med Oral Pathol.* 1991;72:582.
- Lechner J, Mayer W. Immune messengers in neuralgia inducing cavitation osteonecrosis (NICO) in jaw bone and systemic interference. *Eur J Integr Med.* 2010;2(2):71–77.
- Bouquot JE, Margolis M, Shankland W, et al. Through-transmission alveolar ultrasonography (TAU): New technology for evaluation of medullary diseases. Correlation with histopathology of 285 scanned jaw sites. *Oral Surg Oral Med Oral Pathol Oral Radiol Endod.* 2002;94:210.
- Bouquot J, Martin W, Wroblewski G. Computer-based thru-transmission sonography (CTS) imaging of ischemic osteonecrosis of the jaws – a preliminary investigation of 6 cadaver jaws and 15 pain patients. *Oral Surg Oral Med Oral Pathol Oral Radiol Endod.* 2001;92:550.
- Glueck CJ, Freiberg RA, Wang P. Role of thrombosis in osteonecrosis. *Curr Hematol Rep.* 2003;2(5):417–422.
- Jones LC, Mont MA, Le TB, et al. Procoagulants and osteonecrosis. *J Rheumatol.* 2003;30(4):783–791.
- Wilke I, Becker S. Osteonekrose – pathologische Grundlagen. [Osteonecrosis-pathological basics]. *Journal für Mineralstoffwechsel –J Mineral Metabolism.* 2007;14(1):3–6. German
- Lechner J. Herd, Regulation und Information [Focus, regulation and information]. *Hüthig-Verlag Heidelberg*, 1. Auflage 1993, 2. Auflage 1998. German.
- Bouquot JE, LaMarche M. Subpontic osteonecrosis: imaging and microscopic features in 38 patients with “idiopathic” chronic pain. *Oral Surg Oral Med Oral Pathol Oral Radiol Endod.* 1998;86:209–210.
- Arend WP. The balance between IL-1 and IL-1Ra in disease. *Cytokine Growth Factor Rev.* 2003;13(4–5):323–340.
- Levy JA. The unexpected pleiotropic activities of RANTES. *J Immunol.* 2009;182(7):3945–3946.
- Rossi D, Zlotnik A. The biology of chemokines and their receptors. *Annu Rev Immunol.* 2000;18:217–242.
- Bischoff SC, Krieger M, Brunner T, et al. RANTES and related chemokines activate human basophil granulocytes through different G protein-coupled receptors. *Eur J Immunol.* 1993;23(3):761–767.
- Bolin LM, Murray R, Lukacs NW, et al. Primary sensory neurons migrate in response to the chemokine RANTES. *J Neuroimmunol.* 1998;81(1–2):49–57.
- Luo Y, Berman MA, Zhai Q, et al. RANTES stimulates inflammatory cascades and receptor modulation in murine astrocytes. *Glia.* 2002; 39(1):19–30.
- Mrowietz U, Schwenk U, Maune S, et al. The chemokine RANTES is secreted by human melanoma cells and is associated with enhanced tumour formation in nude mice. *Br J Cancer.* 1999;79(7–8): 1025–1031.
- Fischer M, Juremalm M, Olsson N, et al. Expression of CCL5/RANTES by Hodgkin and Reed-Sternberg cells and its possible role in the recruitment of mast cells into lymphomatous tissue. *Int J Cancer.* 2003; 107(2):197–201.
- Ye J. Emerging role of adipose tissue hypoxia in obesity and insulin resistance. *Int J Obes (Lond).* 2009;33(1):54–66.
- Stulnig T. Adipositas und die Entzündung des Fettgewebes [Obesity and adipose tissue inflammation]. *J Klin Endokrinol Stoffw.* 2009; 2(3):17–21. German.
- Kintscher U, Hartge M, Hess K, et al. T-lymphocyte infiltration in visceral adipose tissue: a primary event in adipose tissue inflammation and the development of obesity-mediated insulin resistance. *Arterioscler Thromb Vasc Biol.* 2008;28(7):1304–1310.
- Wu H, Ghosh S, Perrardet XD, et al. T-cell accumulation and regulated on activation, normal T cell expressed and secreted upregulation in adipose tissue in obesity. *Circulation.* 2007;115(8):102–138.
- Huber J, Kiefer FW, Zeyda M, et al. CC chemokine and CC chemokine receptor profiles in visceral and subcutaneous adipose tissue are altered in human obesity. *J Clin Endocrinol Metab.* 2008;93(8): 3215–3221.
- Niwa Y, Akamatsu H, Niwa H, Sumi H, Ozaki Y, Abe A. Correlation of tissue and plasma RANTES levels with disease course in patients with breast or cervical cancer. *Clin Cancer Res.* 2001;7(2):285–289.
- Eichbaum C, Meyer AS, Wang N, et al. Breast cancer cell-derived cytokines, macrophages and cell adhesion: implications for metastasis. *Anticancer Res.* 2011;31(10):3219–3227.
- Suzuki N, Nakajima A, Yoshino S, Matsushima K, Yagita H, Okumura K. Selective accumulation of CCR5+ T lymphocytes into inflamed joints of rheumatoid arthritis. *Int Immunol.* 1999; 11(4):553–559.
- Arima K, Nasu K, Narahara H, Fukisawa K, Matsui N, Miyakawa I. Effects of lipopolysaccharide and cytokines on production of RANTES by cultured human endometrial stromal cells. *Mol Hum Reprod.* 2000; 6(3):246–251.
- Schweigerer L. Basic fibroblast growth factor: properties and clinical implications. In: Habenicht A, editor. *Growth Factors, Differentiation Factors, and Cytokines.* Berlin: Springer; 1990:42–66.
- Nguyen M, Watanabe H, Budson AE, Richie JP, Hayes DF, Folkman J. Elevated levels of an angiogenic peptide, basic fibroblast growth factor, in urine of bladder cancer patients. *J Natl Cancer Inst.* 1993;85(3):241–242.
- Chodak GW, Hospelhorn V, Judge S, et al. Increased levels of fibroblast growth factor-like activity in urine from patients with bladder or kidney cancer. *Cancer Res.* 1988;48(8):2083–2088.
- Tanimoto H, Yoshida K, Yokozaki H, et al. Expression of basic fibroblast growth factor in human gastric carcinomas. *Virchows Arch B Cell Pathol Incl Mol Pathol.* 1991;61(4):263–267.
- Czubayko F, Liaudet-Coopman ED, Aigner A, Tuveson AT, Berchem GJ, Wellstein A. A secreted FGF-binding protein can serve as the angiogenic switch in human cancer. *Nat Med.* 1997;3(10):1137–1140.
- Baird A, Klagsbrun M. The fibroblast growth factor family. *Cancer Cells.* 1991;3(6):239–243.
- Robak E, Woźniacka A, Sysa-Jedrzejowska A, Stepień H, Robak T. Serum levels of angiogenic cytokines in systemic lupus erythematosus and their correlation with disease activity. *Eur Cytokine Netw.* 2001; 12(3):445–452.
- Polnaszek N, Kwabi-Addo B, Peterson LE, et al. Fibroblast growth factor 2 promotes tumor progression in an autochthonous mouse model of prostate cancer. *Cancer Res.* 2003;15:63(18):5754–5760.
- Sato N, Watabe Y, Suzuki H, Shimazaki J. Progression of androgen-sensitive mouse tumor (Shionogi carcinoma 115) to androgen-insensitive tumor after long-term removal of testosterone. *Jpn J Cancer Res.* 1993;84(12):1300–1308.
- Weidner N, Carroll PR, Flax J, Blumenfeld W, Folkman J. Tumor angiogenesis correlates with metastasis in invasive prostate cancer. *Am J Pathol.* 1993;43(2):401–409.
- Russell PJ, Bennett S, Stricker P. Growth factor involvement in progression of prostate cancer. *Clin Chem.* 1998;44(4): 705–723.
- Kwabi-Addo B, Ozen M, Ittmann M. The role of fibroblast growth factors and their receptors in prostate cancer. *Endocr Relat Cancer.* 2004;11(4):709–724.
- George ML, Eccles SA, Tutton MG, Abulafi AM, Swift RI. Correlation of plasma and serum vascular endothelial growth factor levels with platelet count in colorectal cancer: clinical evidence of platelet scavenging? *Clin Cancer Res.* 2000;6(8):3147–3152.

41. Le Page C, Ouellet V, Madore J, et al. From gene profiling to diagnostic markers: IL-18 and FGF-2 complement CA125 as serum-based markers in epithelial ovarian cancer. *Int J Cancer*. 2006;118(7):1750–1758.
42. Bilgic I, Ozalp N, Tez M, Koc M. Serum bFGF concentrations in gastric cancer patients. *Bratisl Lek Listy*. 2008;109(1):8–9.
43. Giri D, Ropiquet F, Ittmann M. Alterations in expression of basic fibroblast growth factor (FGF) 2 and its receptor FGFR-1 in human prostate cancer. *Clin Cancer Res*. 1999;5(5):1063–1071.
44. Dabrosin C. Positive correlation between estradiol and vascular endothelial growth factor but not fibroblast growth factor-2 in normal human breast tissue in vivo. *Clin Cancer Res*. 2005;11(22):8036–8041.
45. Relf M, LeJeune S, Scott PA, et al. Expression of the angiogenic factors vascular endothelial cell growth factor, acidic and basic fibroblast growth factor, tumor growth factor beta-1, platelet-derived endothelial cell growth factor, placenta growth factor, and pleiotrophin in human primary breast cancer and its relation to angiogenesis. *Cancer Res*. 1997;57(5):963–969.
46. Smith K, Fox SB, Whitehouse R, et al. Upregulation of basic fibroblast growth factor in breast carcinoma and its relationship to vascular density, oestrogen receptor, epidermal growth factor receptor and survival. *Ann Oncol*. 1999;10(6):707–713.
47. Soria G, Ben-Baruch A. The inflammatory chemokines CCL2 and CCL5 in breast cancer. *Cancer Lett*. 2008;267(2):271–285.
48. Niwa Y, Akamatsu H, Niwa H, Sumi H, Ozaki Y, Abe A. Correlation of tissue and plasma RANTES levels with disease course in patients with breast or cervical cancer. *Clin Cancer Res*. 2001;7(2):285–289.
49. Azenshtein E, Luboshits G, Shina S, et al. The CC chemokine RANTES in breast carcinoma progression: regulation of expression and potential mechanisms of promalignant activity. *Cancer Res*. 2002;62(4):1093–1102.
50. Eissa SA, Zaki SA, El-Maghraby SM, Kadry DY. Importance of serum IL-18 and RANTES as markers for breast carcinoma progression. *J Egypt Natl Canc Inst*. 2005;17(1):51–55.
51. Zischek C, Niess H, Ischenko I, et al. Targeted stem cell based RANTES/TK suicide gene-therapy in a murine pancreatic cancer tumour model. *Deutsche Gesellschaft für Chirurgie*. 2009;38:3–5. German with English abstract.
52. Tsukishiro S, Suzumori N, Nishikawa H, Arakawa A, Suzumori K. Elevated serum RANTES levels in patients with ovarian cancer correlate with the extent of the disorder. *Gynecol Oncol*. 2006;102(3):542–545.
53. Karnoub AE, Dash AB, Vo AP, et al. Mesenchymal stem cells within tumour stroma promote breast cancer metastasis. *Nature*. 2007;449(7162):557–563.
54. Fang J, Huang S, Liu H, Crepin M, Xu T, Liu J. Role of FGF-2/FGFR signaling pathway in cancer and its signification in breast cancer. *Chinese Sci Bull*. 2003;48(15):1539–1547.
55. Rathanaswami P, Hachicha M, Sadick M, Schall TJ, McColl SR. Expression of the cytokine RANTES in human rheumatoid synovial fibroblasts. Differential regulation of RANTES genes by inflammatory cytokines. *J Biol Chem*. 1993;268(8):5834–5839.
56. Hirano F, Kobayash A, Hirano Y, Nomura Y, Fukawa E, Makino I. Thrombin-induced expression of RANTES mRNA through protease activated receptor-1 in human synovial fibroblasts. *Ann Rheum Dis*. 2002;61(9):834–837.
57. Volin MV, Shah MR, Tokuhira M, Haines GK, Woods JM, Koch AE. RANTES expression and contribution to monocyte chemotaxis in arthritis. *Clin Immun Immunopathol*. 1998;89(1):44–53.
58. Robinson E, Keystone EC, Schall TJ, Gillett N, Fish EN. Chemokine expression in rheumatoid arthritis (RA): evidence of RANTES and macrophage inflammatory protein (MIP)-1 beta production by synovial T cells. *Clin Exp Immunol*. 1995;101(3):398–407.
59. Wang CR, Guo HR, Liu MF. RANTES promoter polymorphism as a genetic risk factor for rheumatoid arthritis in the Chinese. *Clin Exp Rheumatol*. 2005;23(3):379–384.
60. Yao TC, Kuo ML, See LC, et al. RANTES and monocyte chemoattractant protein 1 as sensitive markers of disease activity in patients with juvenile rheumatoid arthritis: a six-year longitudinal study. *Arthritis Rheum*. 2006;54(8):2585–2593.
61. Sarchielli P, Di Filippo M, Ercolani MV, et al. Fibroblast growth factor-2 levels are elevated in the cerebrospinal fluid of multiple sclerosis patients. *Neurosci Lett*. 2008;435(3):223–228.
62. Su JJ, Osoegawa M, Matsuoka T, et al. Upregulation of vascular growth factors in multiple sclerosis: correlation with MRI findings. *J Neurol Sci*. 2006;243(1–2):21–30.
63. Johansson A, Larsson A, Nygren I, Blennow K, Askmark H. Increased serum and cerebrospinal fluid FGF-2 levels in amyotrophic lateral sclerosis. *Neuroreport*. 2003;14(14):1867–1869.

International Journal of General Medicine

Publish your work in this journal

The International Journal of General Medicine is an international, peer-reviewed open-access journal that focuses on general and internal medicine, pathogenesis, epidemiology, diagnosis, monitoring and treatment protocols. The journal is characterized by the rapid reporting of reviews, original research and clinical studies across all disease areas.

Submit your manuscript here: <http://www.dovepress.com/international-journal-of-general-medicine-journal>

Dovepress

A key focus is the elucidation of disease processes and management protocols resulting in improved outcomes for the patient. The manuscript management system is completely online and includes a very quick and fair peer-review system. Visit <http://www.dovepress.com/testimonials.php> to read real quotes from published authors.